

# Letter in Reply: Leiomyosarcoma of the Vulva Mimicking as Chronic Bartholin Cyst: A Case Report

Shabnam Saquib<sup>1\*</sup> and Tasnim Riasath Keloth<sup>2</sup>

<sup>1</sup>Department of Obstetrics and Gynecologist, Dubai Hospital, Dubai, UAE

<sup>2</sup>Department of Pathology, Dubai Hospital, Dubai, UAE

## ARTICLE INFO

### Article history:

Received: 4 October 2020

Accepted: 4 October 2020

## ONLINE:

DOI 10.5001/omj.2021.70

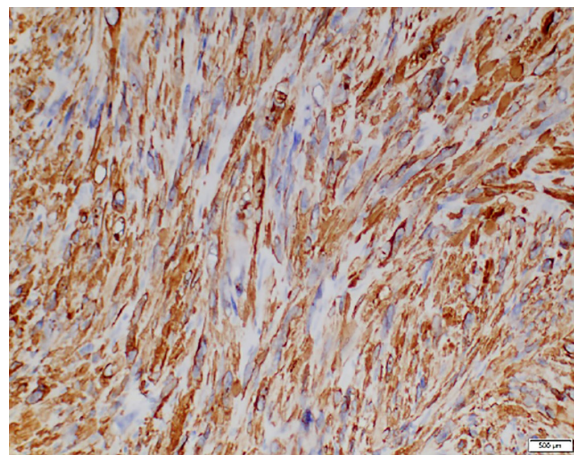
Dear Editor,

We appreciate the author's positive comments about our article published in the July 2020 issue of the *Oman Medical Journal*.<sup>1,2</sup>

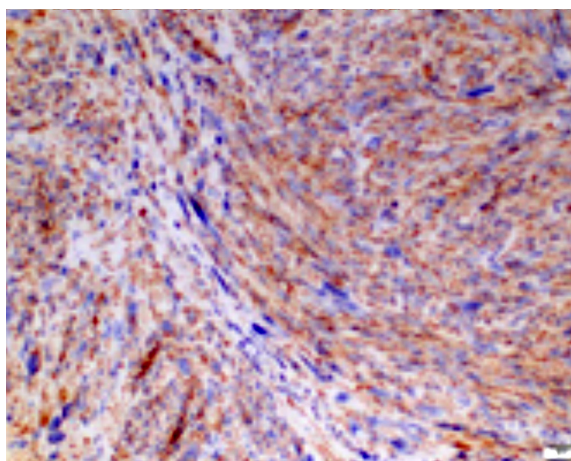
We agree with your suggestion to include pre- and intraoperative and macroscopic figures to give more information and knowledge for the readers. Our patient gave us consent to publish the case, understanding that it is a very rare pathology. From an ethical point of view and to respect the patients' autonomy and confidentiality, we submitted only microscopic pictures as the diagnostic criteria of leiomyosarcoma.<sup>3,4</sup>

Immunohistochemistry helps to confirm the diagnosis. Our patient tumor cells showed diffuse strong positive staining for smooth muscle actin, caldesmon, and desmin. The Ki-67

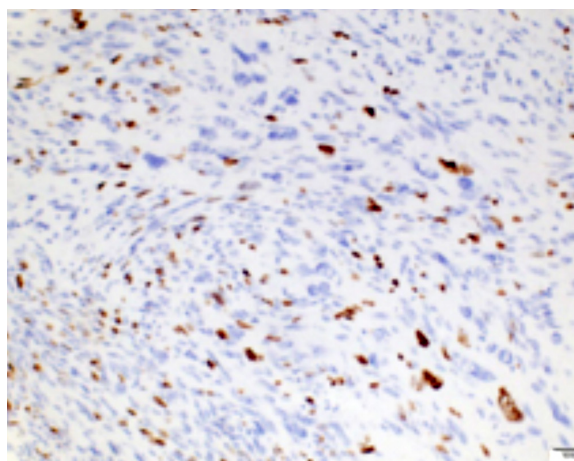
(MIB-1) proliferation index was around 30%. Negative staining was observed for CD117,



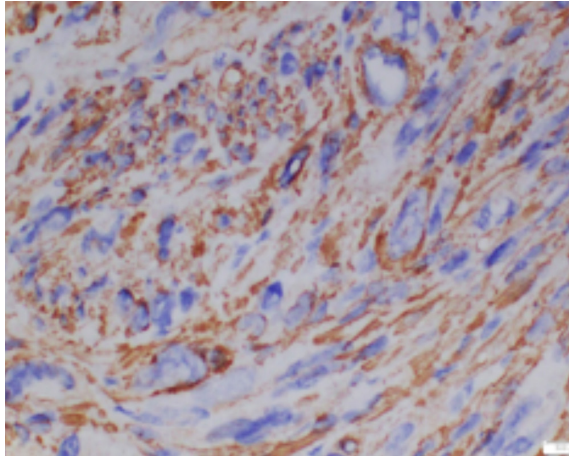
**Figure 2:** Spindled tumor cells showing immunoreactivity for desmin, magnification = 400 ×.



**Figure 1:** Immunohistochemistry positive for caldesmon, magnification = 200 ×.



**Figure 3:** Tumor cells show positive (nuclear) reaction for Ki 67 (MIB-1), magnification = 400 ×.



**Figure 4:** Tumor cells show a strong positive reaction for spinal muscular atrophy, magnification = 400 ×.

CD4, vimentin, and S100 [Figures 1–4]. The

histomorphological features and immunoprofile were consistent with leiomyosarcoma grade 2, according to the French Federation of Cancer Centers Sarcoma Group grading system.<sup>2,5</sup>

#### REFERENCES

1. Hayati F, Soe MZ, Azizan N, Payus AL. The Value of Preoperative Diagnosis in Leiomyosarcoma of the Vulva. *Oman Med J* 2021;36(2):e256.
2. Saquib S, Cherawala M, Rahman OA, Keloth TE. Leiomyosarcoma of the vulva mimicking as chronic Bartholin cyst: a case report. *Oman Med J* 2020;35(4):e153.
3. Santos P, Hespanhol A. Informed consent for case reports - an ethical perspective. *Acta Bioethica* 2017;23(2):271-278.
4. Committee on Publication Ethics (COPE). Code of conduct and best practice guidelines for journal editors. 2011 [cited 2015 September]. Available from: [www.publicationethics.org](http://www.publicationethics.org).
5. Smith SA, Bou Zgheib N, Vallejos AM, Cuda JD. Case report on leiomyosarcoma of the vulva: a rare pathology. *Marshall Journal of Medicine* 2020;6(3):6.